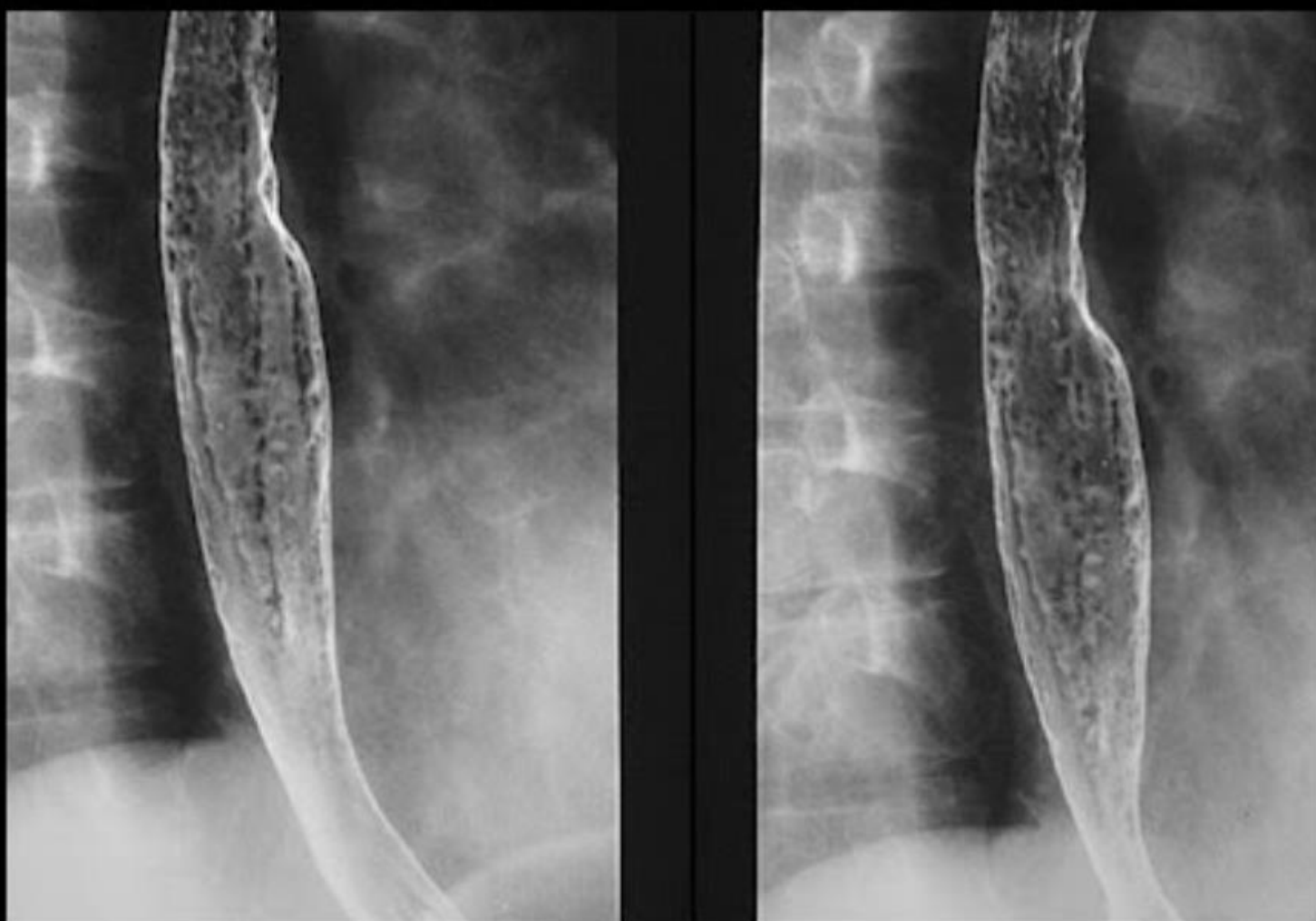



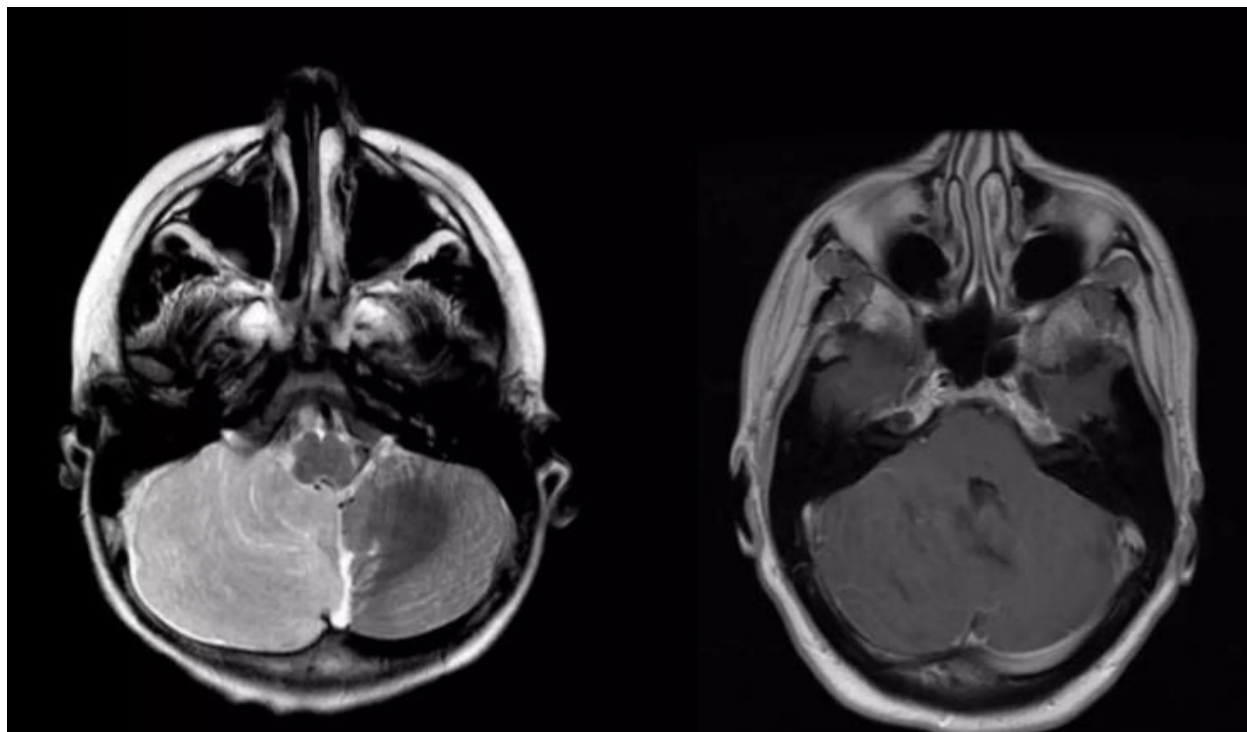
2025

KARNATAKA RADIOLOGY EDUCATION PROGRAM

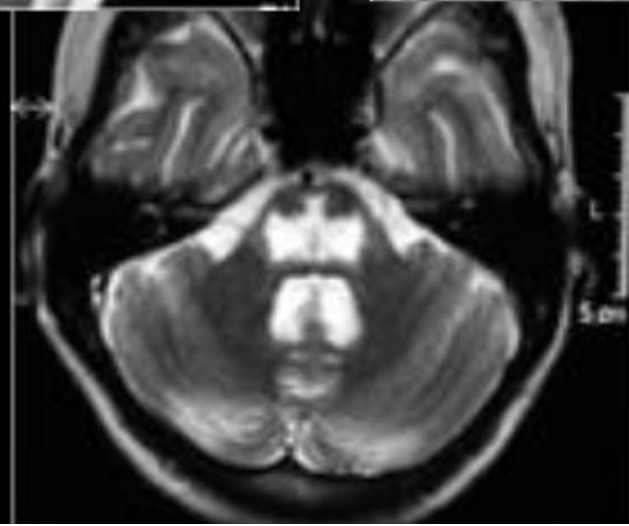
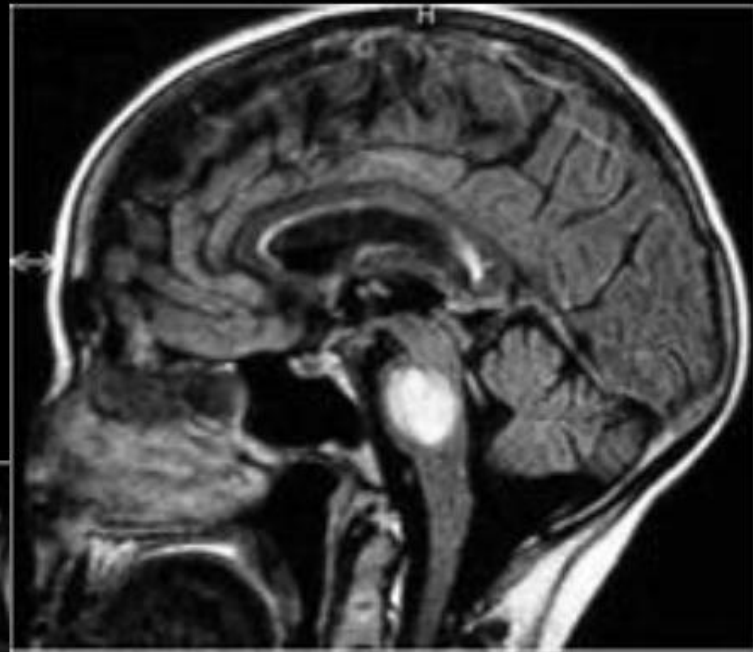
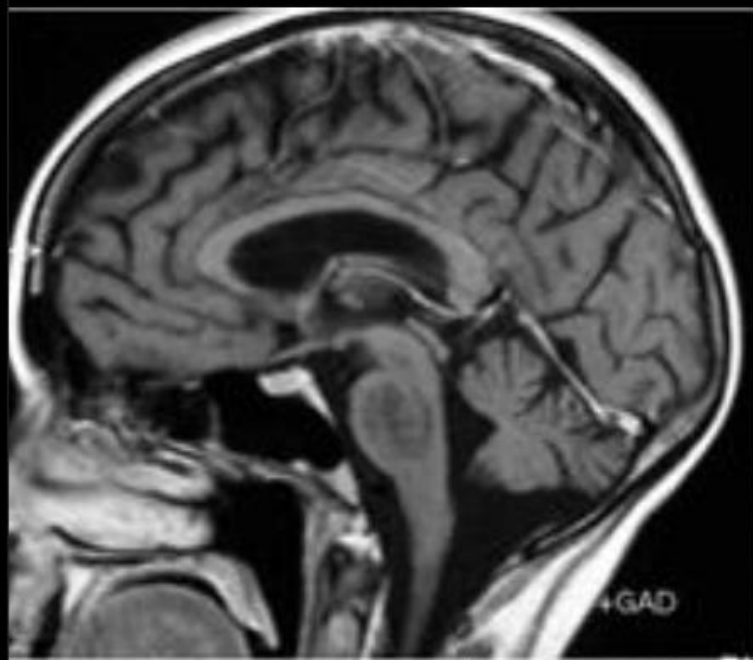Spotters



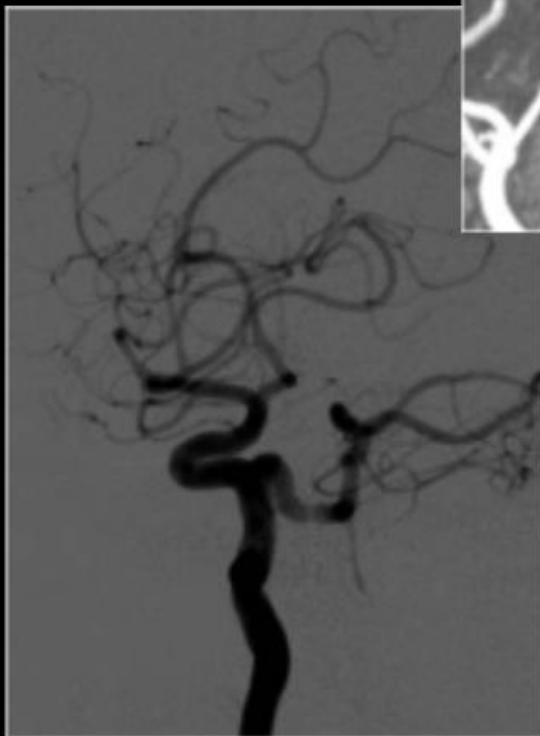
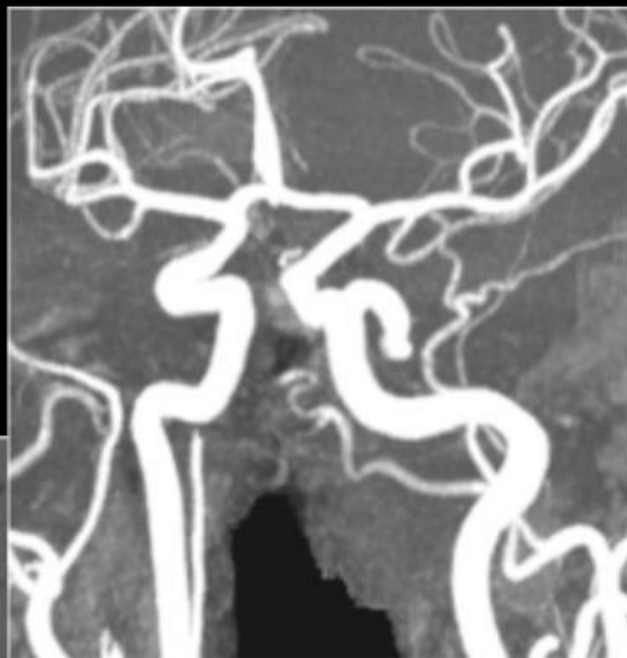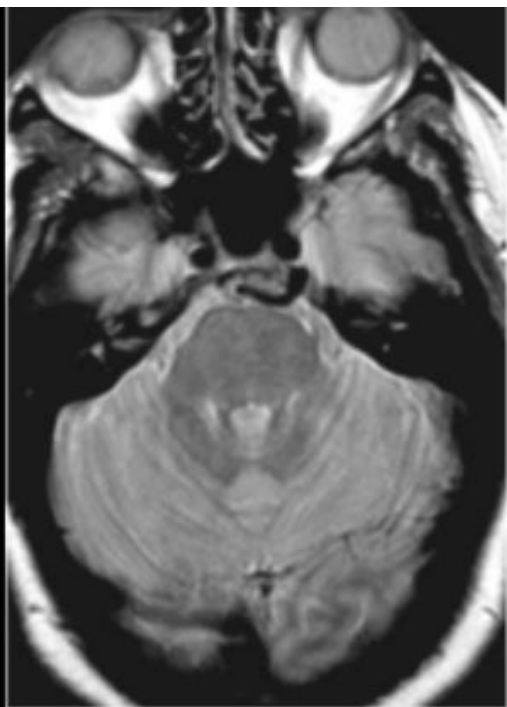
Candida esophagitis



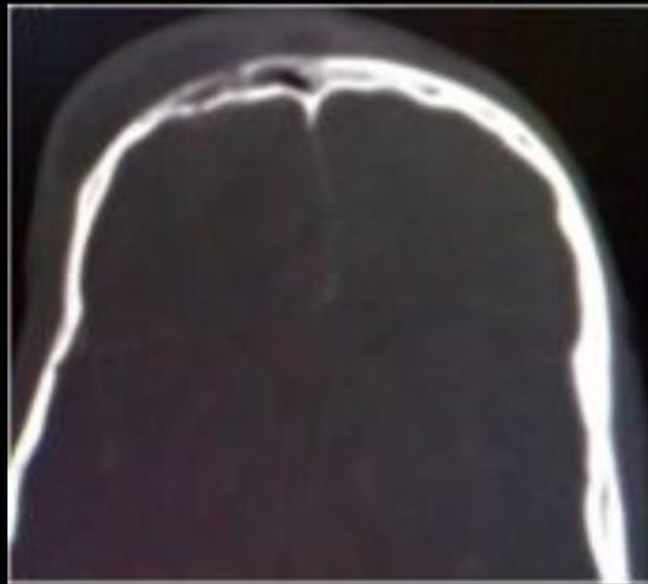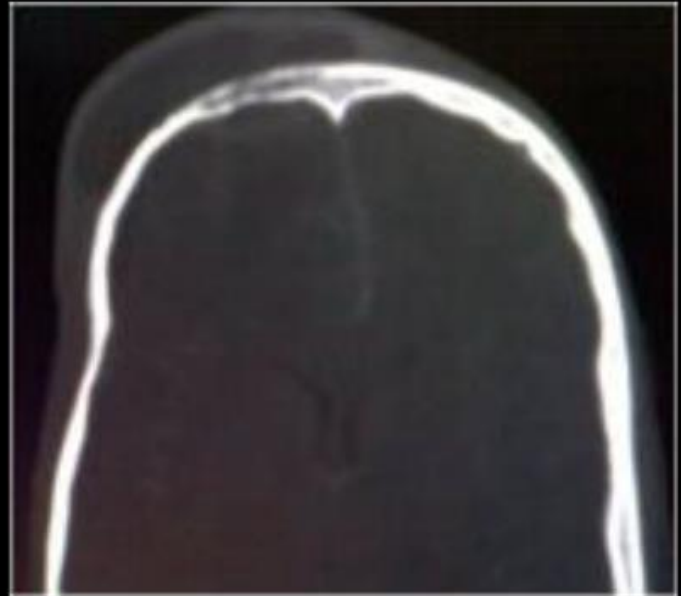
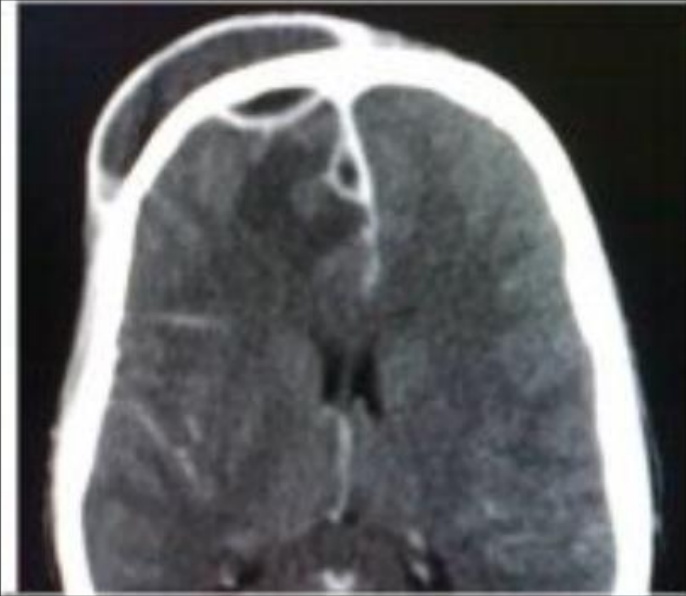Lhermitte Duclos disease



Osmotic demyelination syndrome



Persistent Trigeminal Artery



Pott Puffy tumour